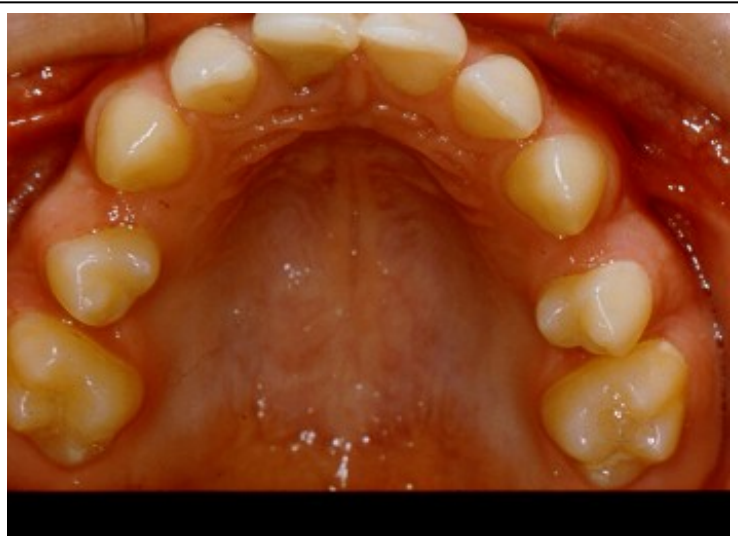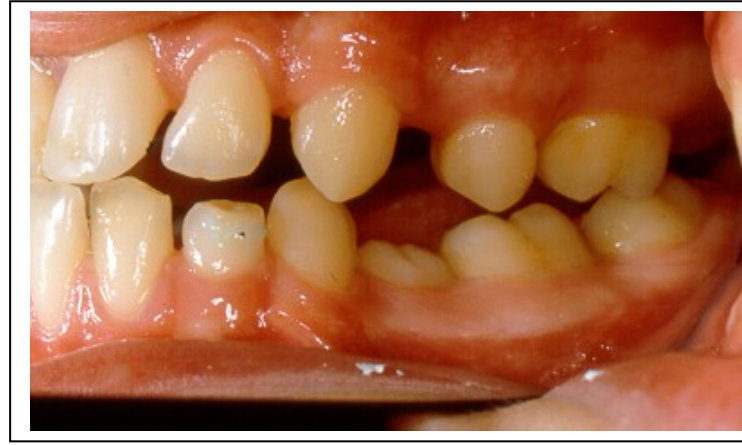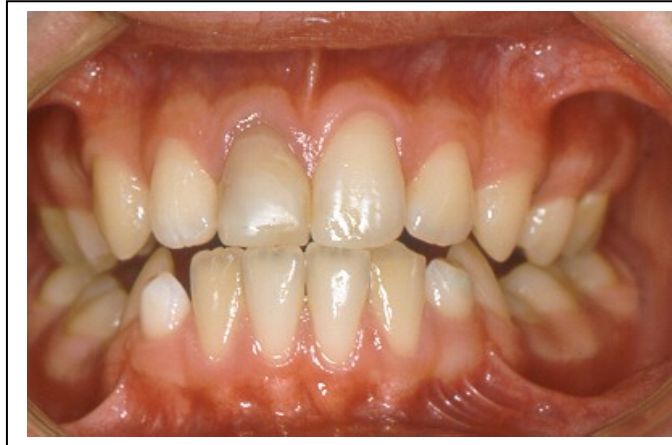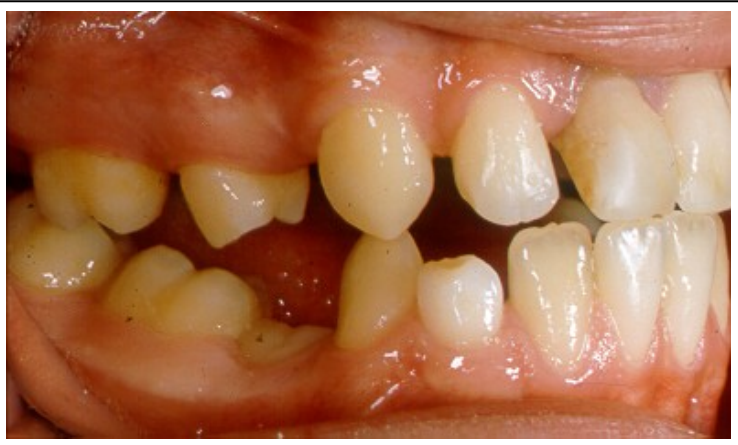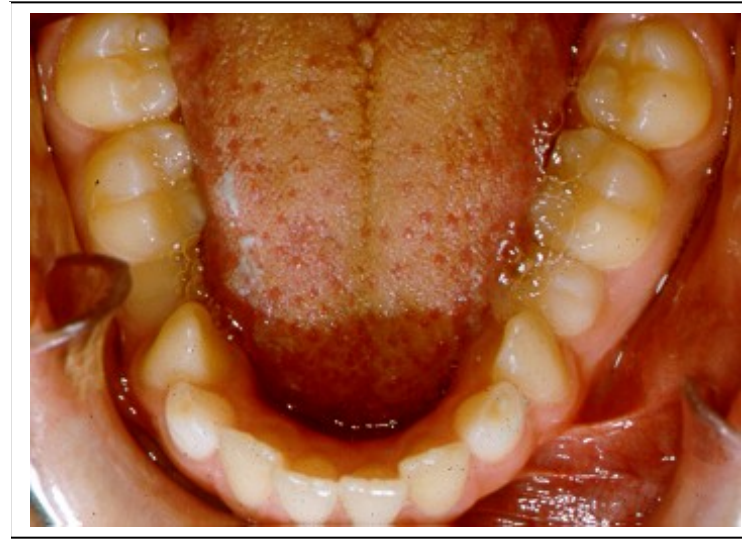




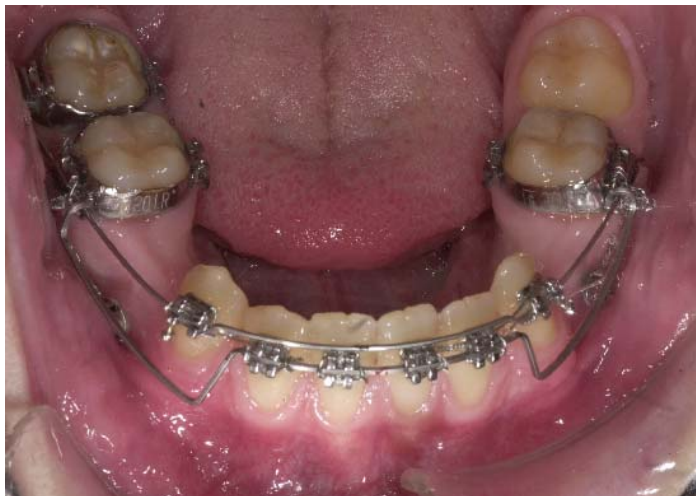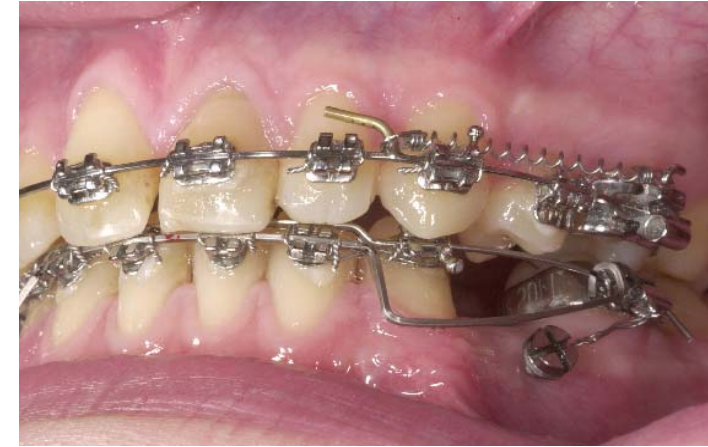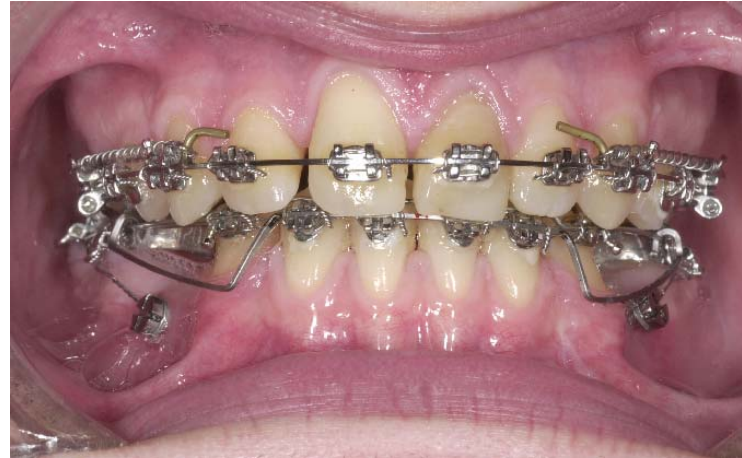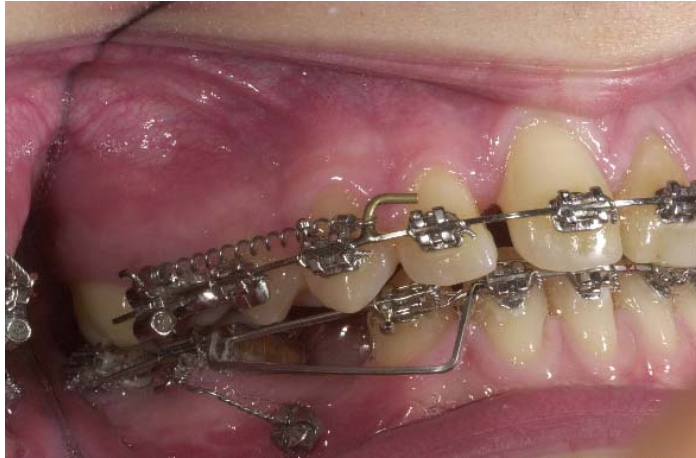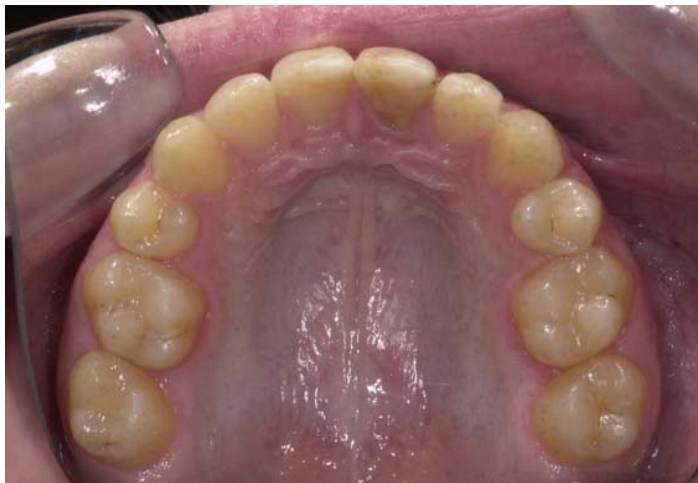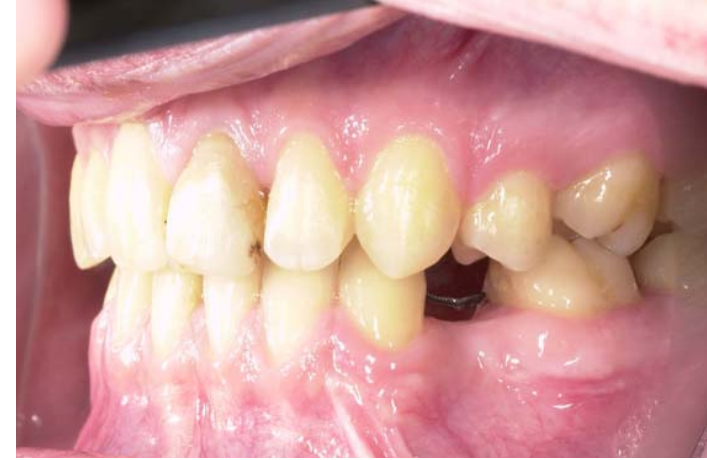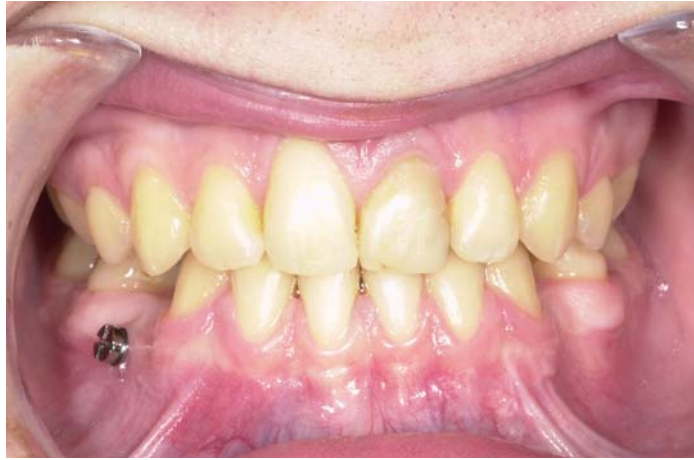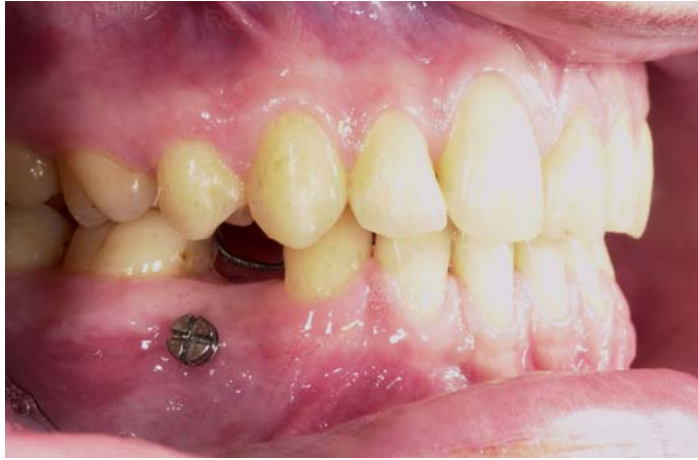13 year old boy with
agenesis of 2 upper and 4
lower incisors. Persistence
of deciduous lower
canines. Left upper
incisor endodontically
treated following a trauma





Two mini-implants were inserted distal to the lower canines, that were moved forward. The implants served first as direct anchorage for the mesial movement of the molars, then as indirect anchorage for the mesial displacement of the anterior segment and additionally as anchorage for a class III traction bringing the upper molars forward (not shown).



End of treatment .Now
only two implant have to
be inserted in the lower
jaw at the end of growth

